

**10. DISEASES OF THE GENITOURINARY SYSTEM (580-629)**

**NEPHRITIS, NEPHROTIC SYNDROME, AND NEPHROSIS (580-589)**

**EXCLUDES** *hypertensive chronic kidney disease (403.00-403.91, 404.00-404.93)*

**580 Acute glomerulonephritis**

**INCLUDES** acute nephritis

**DEF:** Acute, severe inflammation in tuft of capillaries that filter the kidneys.

**580.0 With lesion of proliferative glomerulonephritis**

Acute (diffuse) proliferative glomerulonephritis  
Acute poststreptococcal glomerulonephritis

**580.4 With lesion of rapidly progressive glomerulonephritis**

Acute nephritis with lesion of necrotizing glomerulitis

**DEF:** Acute glomerulonephritis; progresses to ESRD with diffuse epithelial proliferation.

**580.8 With other specified pathological lesion in kidney**

**580.81 Acute glomerulonephritis in diseases classified elsewhere**

*Code first underlying disease, as:*  
infectious hepatitis (070.0-070.9)  
mumps (072.79)  
subacute bacterial endocarditis (421.0)  
typhoid fever (002.0)

**580.89 Other**

Glomerulonephritis, acute, with lesion of:  
exudative nephritis  
interstitial (diffuse) (focal) nephritis

**580.9 Acute glomerulonephritis with unspecified pathological lesion in kidney**

|                        |                      |
|------------------------|----------------------|
| Glomerulonephritis NOS | } specified as acute |
| hemorrhagic            |                      |
| Nephritis              |                      |
| Nephropathy            |                      |

**581 Nephrotic syndrome**

**DEF:** Disease process marked by symptoms such as; extensive edema, notable proteinuria, hypoalbuminemia, and susceptibility to intercurrent infections.

**581.0 With lesion of proliferative glomerulonephritis**

**581.1 With lesion of membranous glomerulonephritis**

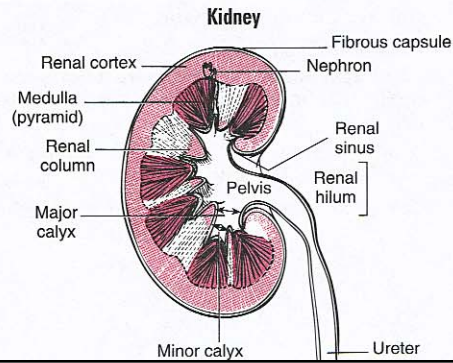
Epimembranous nephritis  
Idiopathic membranous glomerular disease  
Nephrotic syndrome with lesion of:  
focal glomerulosclerosis  
sclerosing membranous glomerulonephritis  
segmental hyalinosis

**581.2 With lesion of membranoproliferative glomerulonephritis**

Nephrotic syndrome with lesion (of):

|                      |                      |
|----------------------|----------------------|
| endothelial          | } glomerulonephritis |
| hypocomplementemic   |                      |
| persistent           |                      |
| lobular              |                      |
| mesangiocapillary    |                      |
| mixed membranous and |                      |
| proliferative        |                      |

**DEF:** Glomerulonephritis combined with clinical features of nephrotic syndrome; characterized by uneven thickening of glomerular capillary walls and mesangial cell increase; slowly progresses to ESRD.



Code 581.8: delete check fourth- digit symbol; add check fifth-digit symbol **5th**

Minimal change:  
glomerular disease  
glomerulitis  
nephrotic syndrome

AHA: 10, '07, 23

**581.8 With other specified pathological lesion in kidney**

**581.81 Nephrotic syndrome in diseases classified elsewhere**

*Code first underlying disease, as:*  
amyloidosis (277.30-277.39)  
diabetes mellitus ▶(249.4, 250.4)◀  
tes mellitus (250.4)  
malaria (084.9)  
polyarteritis (446.0)  
systemic lupus erythematosus (710.0)

**EXCLUDES** *nephrosis in epidemic hemorrhagic fever (078.6)*

AHA: 30, '91, 8, 12; S-0, '85, 3

**581.89 Other**

Glomerulonephritis with edema and lesion of:  
exudative nephritis  
interstitial (diffuse) (focal) nephritis

**581.9 Nephrotic syndrome with unspecified pathological lesion in kidney**

Glomerulonephritis with edema NOS  
Nephritis:  
nephrotic NOS  
with edema NOS  
Nephrosis NOS  
Renal disease with edema NOS

