
ABSTRACT

The brachial plexus is a tangle of nerves that can be difficult to master. However, this nerve jumble is quickly learned with the technique described. Different specialists need to memorize different parts of the plexus.

Learn the Brachial Plexus in Five Minutes or Less

By Daniel S. Romm, M.D.
Chief, Physical Medicine and Rehabilitation
Department of Veterans Affairs
Biloxi, Mississippi
And Dennis A. Chu, M.D.

This material is the result of work supported with resources and the use of facilities at the Gulf Coast Veterans Health Care System.

This reflects the authors' personal views and in no way represents the official view of the Department of Veterans Affairs of the U.S. Government.



INTRODUCTION

The brachial plexus, neural connections between the neck and brachial nerves, is a morass that makes the Los-Angeles highway system look like a straight line. However, memorizing the brachial plexus is a daunting task that every medical student must do.


A review of the literature and books on brachial plexus revealed that the following easy method of learning the brachial plexus has never been published before:

METHOD

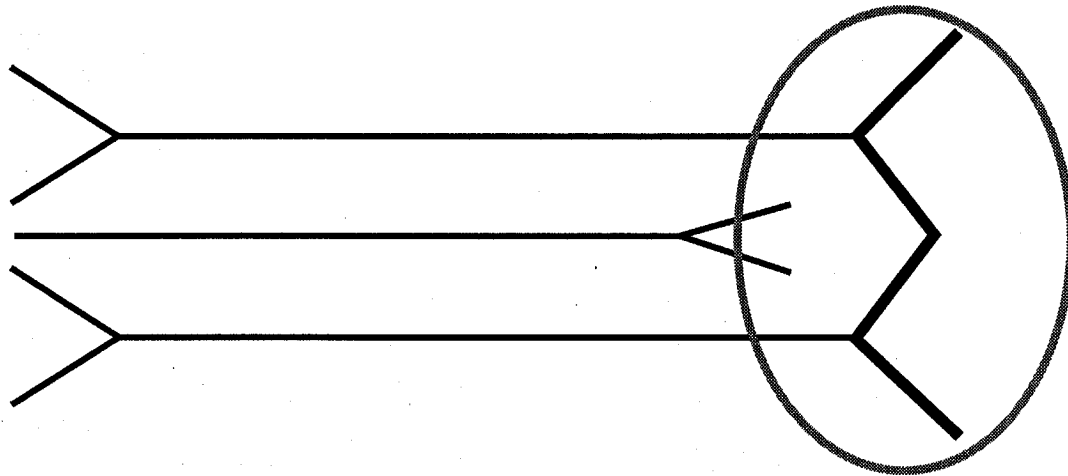
1. Draw two headless arrows to the right.



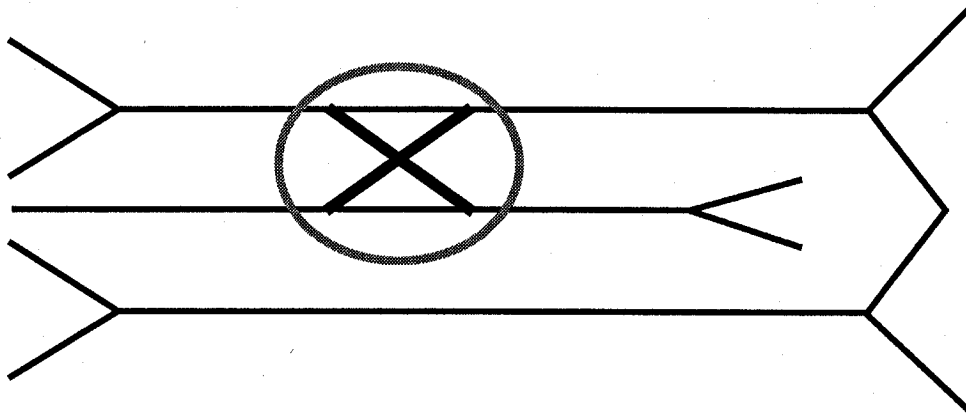
2. Add a headless arrow to the left.



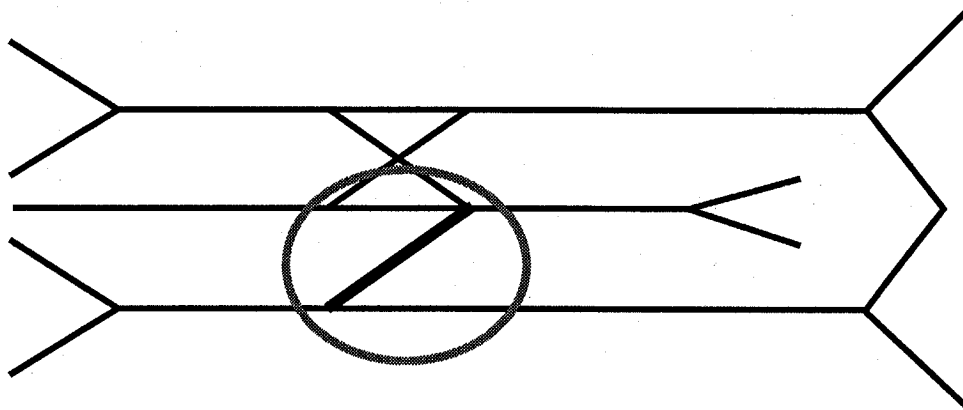
3. Add a "W".



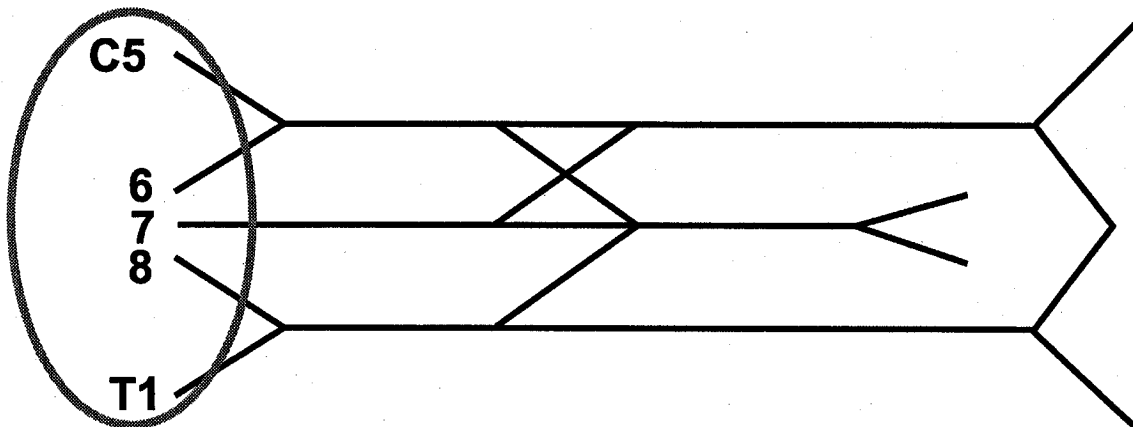
4. Add an "X".



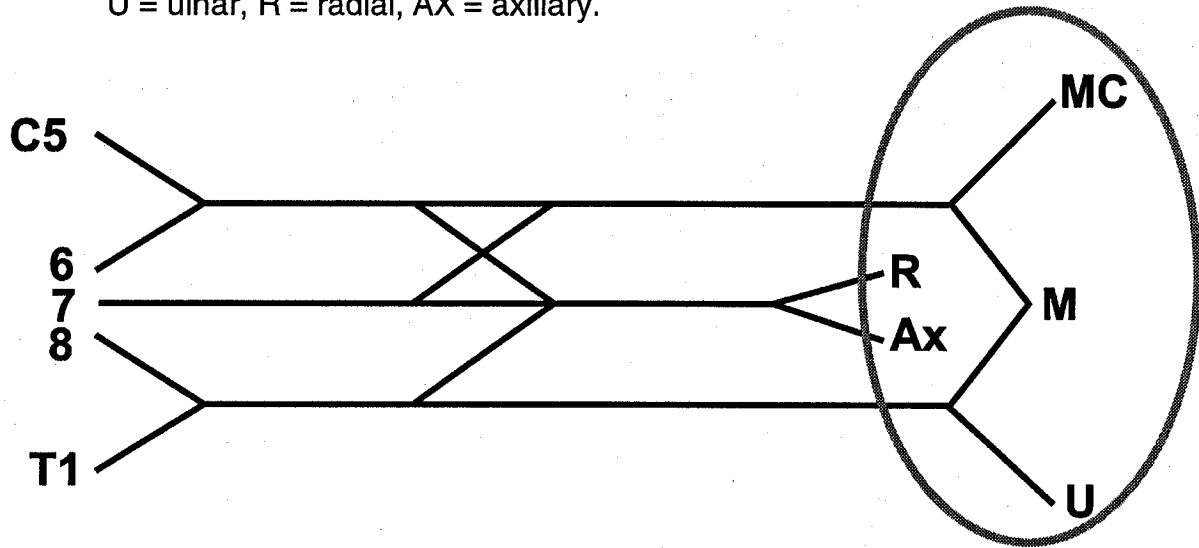
5. Add a "Y". (Note: Just a branch of the "Y" is added.)



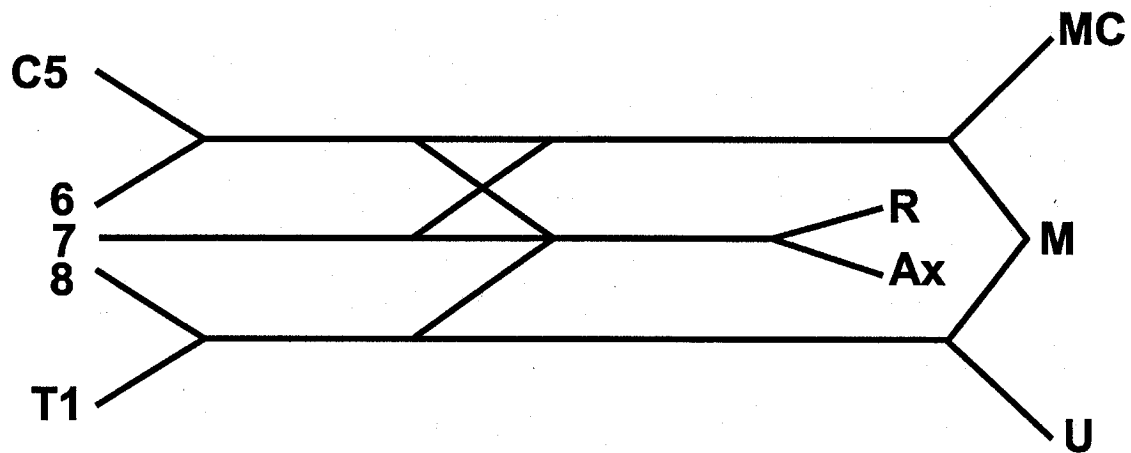
6. Label C5 to T1.



7. Label the major branches: MC = musculocutaneous, M = median,
U = ulnar, R = radial, AX = axillary.

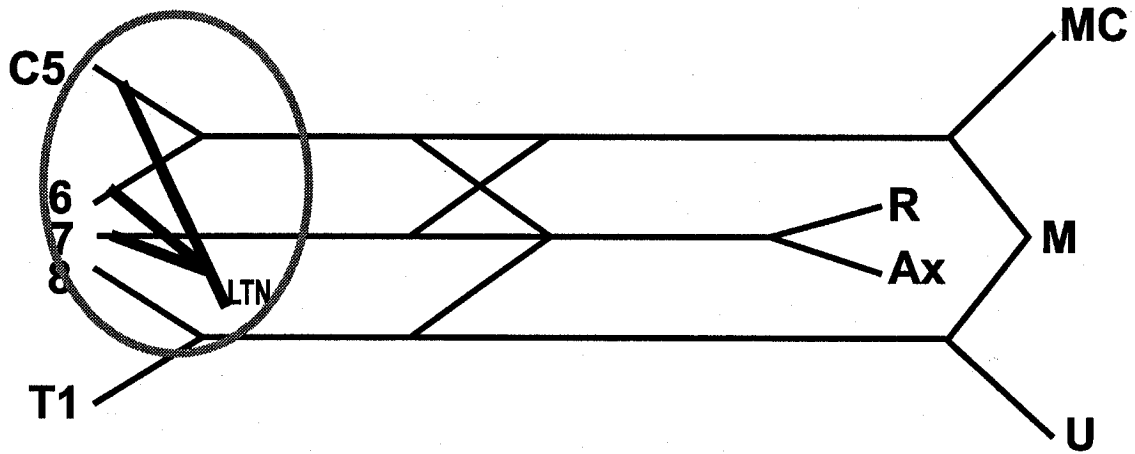


That's it! Well, that's largely it.

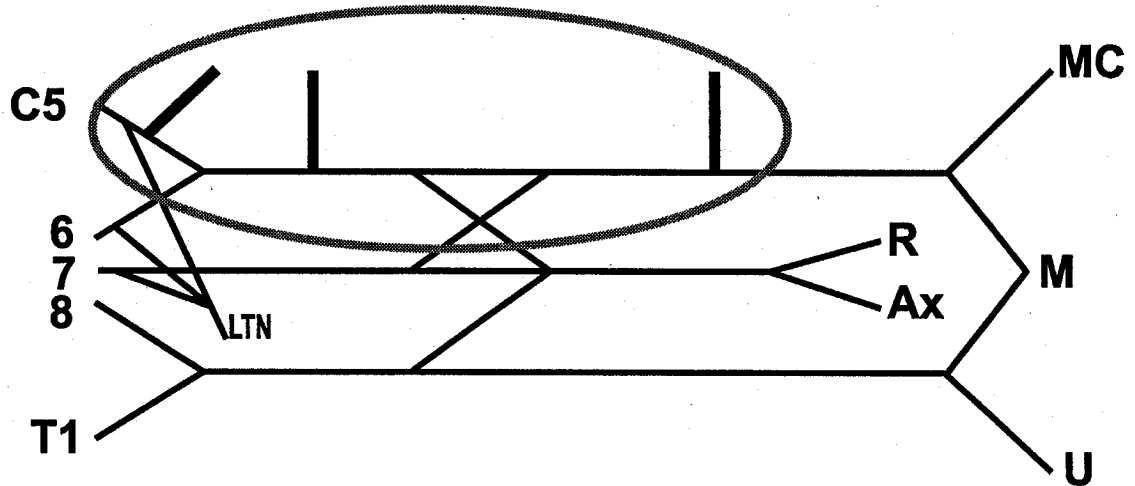


The above method draws the main branches and main nerve roots with the proper connections. This knowledge is adequate for medical students, interns, most residents, and most physicians. Some doctors, for instance, neurosurgeons, neurologists and physiatrists will probably want to learn the four "threes" that need to be added, as follows:

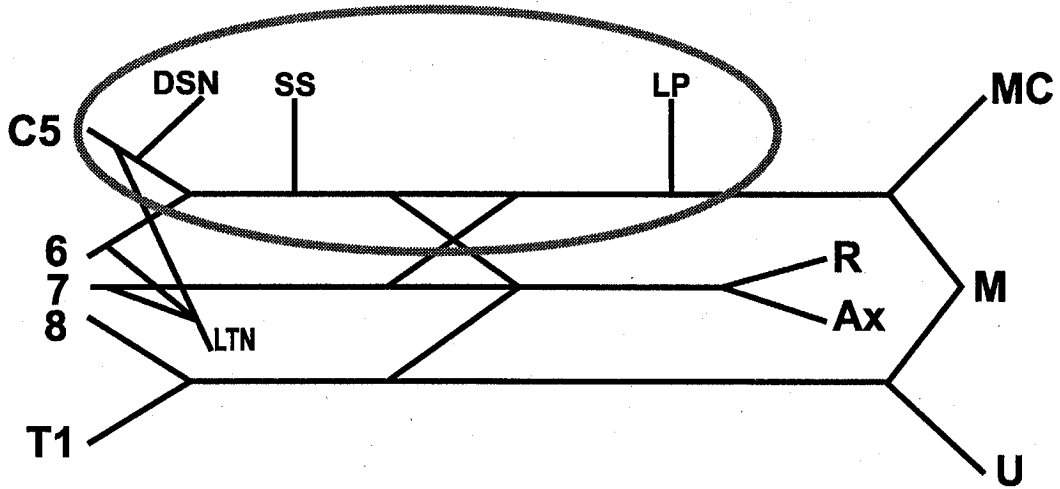
8. The first "3" is the branches to C5, 6, and 7 which form LTN = long thoracic nerve.



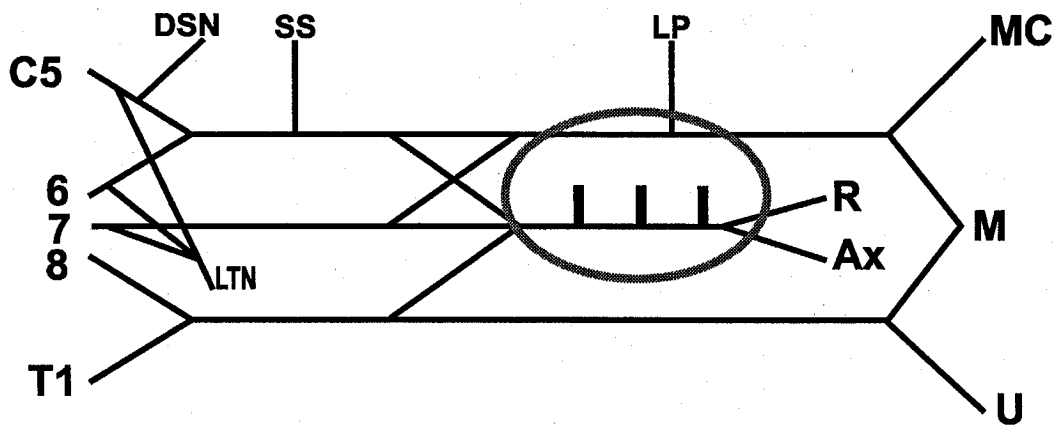
9. Next, each of the headless arrows has three nerves attached to it.
To the top headless arrow, add its "3".



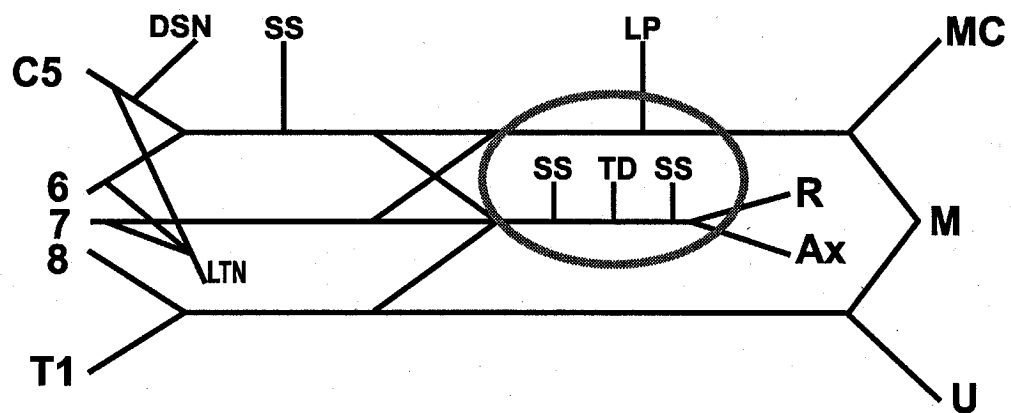
10. Label these three: DSN = dorsoscapular nerve; SS = suprascapular nerve; LP = lateral pectoral nerve.



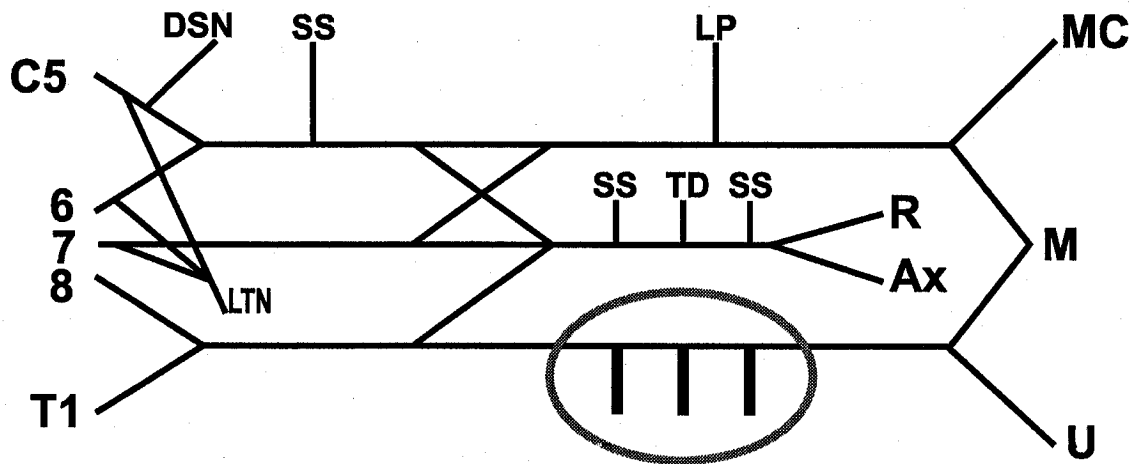
11. Add the "3" to the middle headless arrow.



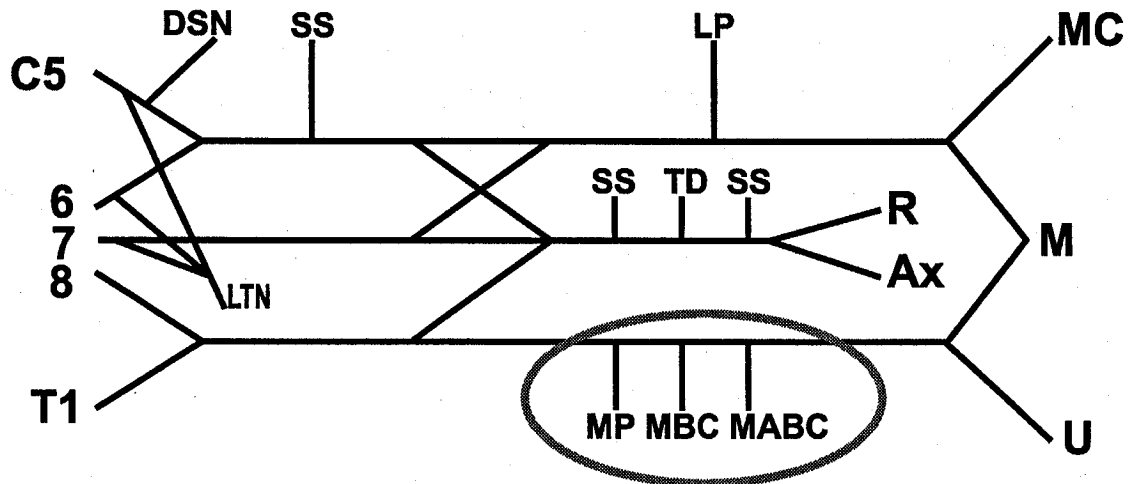
12. Label the second headless arrow "3" as follows: SS = subscapular, TD = thoracodorsal nerve.



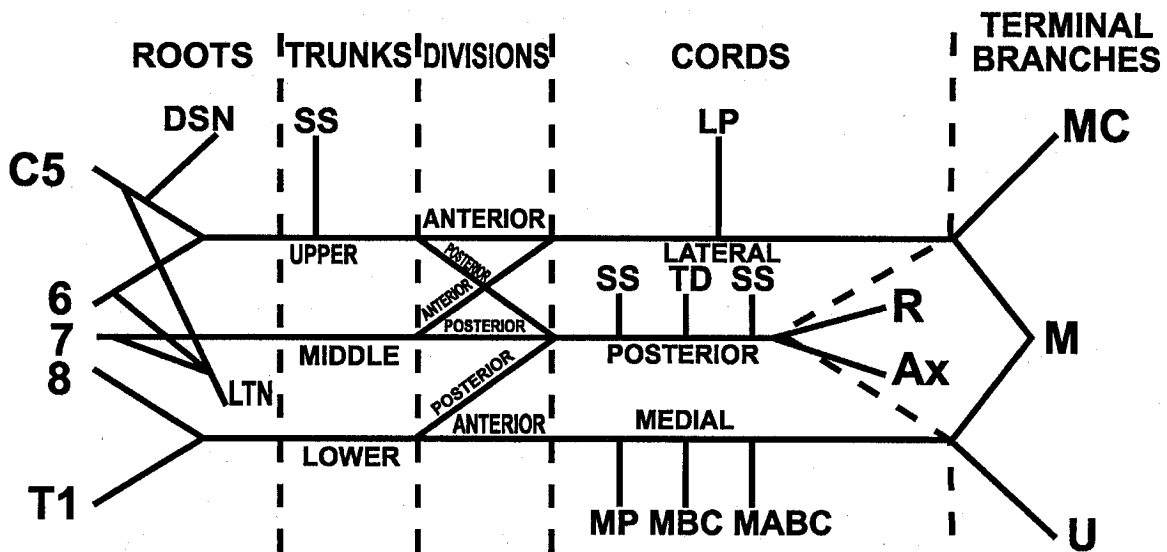
13. Add the final "3" on the bottom headless arrow.



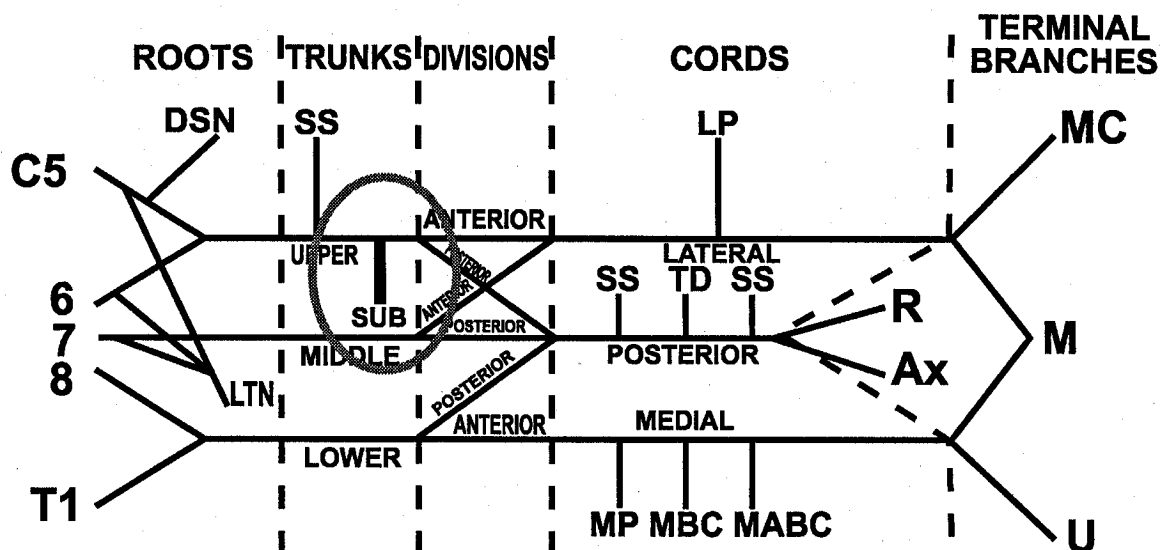
14. Label the last three. Note: MP = medial pectoral, MBC = medial brachial cutaneous, and MABC = medial antebrachial cutaneous. You can remember the order of MBC and MABC because the brachial cutaneous goes to the brachium or arm and the MABC goes to the antebrachium or forearm. Therefore, it makes "sense" that the nerve to the forearm starts distally.



15. Label roots, trunks, divisions, cords, terminal branches.



16. Other doctors, for instance, radiologists, thoracic surgeons and neurosurgeons, may need to identify the based-on-a-review-of-the-literature relatively clinically unimportant nerve to the subclavius (SUB below). These specialists can remember that the first headless arrow has one more branch.



CONCLUSION

Whew! You've learned the brachial plexus in 4 minutes and 30 seconds. Congratulations! A new world's record!

